

Effect of exogenous estradiol on the gross morphology and morphometry of the male chicken (*Gallus domesticus*) gonads

Nirmali, W.K.R.1,2,* , Warnakula, L.1, Cooray, R.1, Hapuarachchi, N.S.1 and Magamage, M.2

1 Section of Genetics, Institute for Research and Development, Colombo, Sri Lanka;

2 Department of Livestock production, Sabaragamuwa University, Sri Lanka

*rameshanirmali@gmail.com

Abstract - Estrogen plays a key role during gonadal differentiation of female chickens. Embryonic exposure to exogenous estrogens had shown a temporary feminization of the male gonads. Therefore the current study was aiming at finding out the feminizing effects of post-hatching continuous exogenous estrogen supply to the gross morphology and the morphometry of in-ovo estrogen treated male chicken gonads with age. Shaver brown chicken eggs were incubated under standard conditions and two in-ovo injections of 20ul of 5mg/ml estradiol cypionate per egg were given to each treated egg and same volume of PBS were injected to control eggs. The male chicks hatched (9 Control and 18 treated) were raised for 2 months feeding according to the feeding schedule given in the “Shaver Brown Management Guide” (Netherland). A half (9) of treated chicks were given with a weekly post-hatching injection of 0.1ul/chick estradiol cypionate intra muscularly (T2) and the rest (9) were raised with no post-hatching injection (T1). 3 chicks from each group including control (C) were sacrificed at 1 week, 4 weeks and 8 weeks intervals and gross morphology and the morphometric measurements were recorded. T1 and T2 chicks showed well-developed and lobulated left gonad which was similar to control female. However the right gonad showed a significant difference between T1 and T2 where T1 chicks showed a very fragile and poorly developed right gonad while T2 showed a prominent right gonad which was similar in color and texture of control male gonads. The weights of both right and left gonads showed significant difference only at the 8th week ($P=0.0199$ and $P=0.0257$) while the width of the left gonad at 1st and 8th weeks showed a significant difference ($P=0.0318$ and $P=0.049$ respectively). In conclusion, male chicken gonads are feminized with embryonic estradiol exposure and the continuous exposure leads to development of the right gonad along with the feminized left gonad.

Keywords - Chicken, Estradiol Cypionate, Feminization, Gonadal morphology, Gonadal morphometry.

INTRODUCTION

The sexual differentiation of chickens which primarily involves the gonadal differentiation takes place during the embryonic development and is regulated by both the direct genetic factors and the hormonal pathways. They initially

have bi-potential gonads during the early embryonic stages and those get differentiated in either to testes or ovary around the day 6 of embryonic development [5].

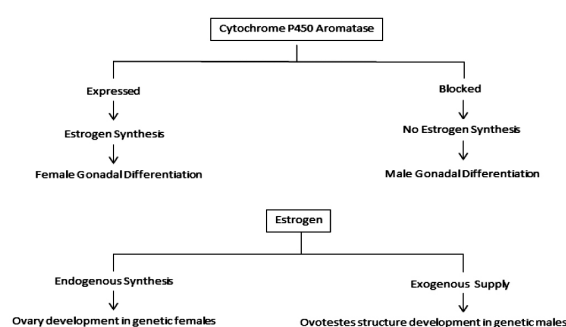


Fig 1: Role of Estrogen in Gonadal Differentiation

According to the literature, Estrogen plays the key role in ovarian differentiation. Therefore various studies had been implemented to see the possibility of manipulation of the gonadal differentiation process by manipulating the Estrogens in early embryonic chickens.

The female to male sex reversal is confirmed to be permanent where genetic females show both anatomical and physiological male characters. However, male to female sex reversal trials show that male sex reversal is either partial or temporary where females transform back to males with the age. The factors underlying this phenomenon i.e why the exogenous hormonal intervention only override the direct genetic factors in female to male sex reversal but not in male to female, still remains a question.

If the direct genetic factors could be overridden by the hormonal regulation in the gonadal differentiation, in female to male sex reversal, there should be another genetic or hormonal regulatory mechanism for the reversible nature of the male to female sex reversal. Assuming the lack of continuous Estrogen production as the possible reason for that, this study was conducted to determine the fate of gross morphology and morphometry of the genetic male chicken gonads with age when a continuous estrogen supply is provided starting from the pre gonadal differentiation stage of the embryo.

MATERIALS AND METHOD

Statement on animals use:

All animal experiments were conducted under the guidance and approval of institutional animal care and use committee recommendations of Sabaragamuwa University of Sri Lanka.

Treatments:

Two treatment groups were designed as T1 where the chicks with only in-ovo estradiol injection while T2 chicks with both in-ovo and post-hatching estradiol injections.

Incubation of eggs and in-ovo injections:

Shaver Brown eggs were incubated under standard conditions. Treatment eggs were injected with Estradiol Cypionate (5mg/ml) (Vemedim Corporation, Vietnam) two doses each of 20ul per egg on the 2nd and the 14th day of incubation to the air cell and sealed with paraffin. The control eggs were injected with same volume of Phosphate Buffered Saline (PBS) using the same procedure.

Genetic sexing:

The genetic sexing of the chicks was performed by Polymerase Chain reaction using a previously described and revalidated, W chromosome linked HUR0424 dominant marker [7] (Table:01). Blood samples for sexing were obtained on the 2nd post-hatching day of chicks. The presence and absence of a 315 bp band in the gel electrogram was interpreted as female and male respectively.

Table 01: Primer details for the genetic sexing of chickens

Fragment Name	A m p l i c o n Size (bp)	Forward Primer (5' to 3')	T ^m
HUR0424 Forward	315	GGTCGGGGAGAGGAATA-AAA	58.4
HUR0424 Reverse		GCACCACAGGCTTACGC-TAT	60.5

Rearing of chicks:

27 male chicks were raised feeding according to the “Shaver Brown Management Guide” (Netherlands).

Post-hatching injection:

A half of in-ovo Estradiol treated male chicks (9) were randomly selected for T1 and T2 treatment groups. The T2 chicks were injected intra muscularly to the breast muscle, using a 31 gauge sterile needle, with 1mL syringe with Estradiol (20ul of 5mg/ml estradiol cypionate per egg) weekly starting from 5th day till the 8th week of post-hatching.

Sacrificing of chicks:

Three male chicks from each group (T1, T2 and C) were randomly selected and sacrificed at 1 week, 4 weeks and 8 weeks old ages. Sacrifice was done by sending an air bubble through the brachial vein.

Data collection:

Following dissection, the gross gonadal morphology was visually assessed compared to the female gonadal morphology described in Vaillant et al., 2001 [2]. Then the length and diameter of each gonad were measured using a Vernier caliper. The weights of each gonad were also measured to analyze the treatment effect.

Data Analysis:

Data were analyzed the using Statistical Analysis Software (SAS) 9.0 version.

RESULTS

Gross Gonadal Morphology:

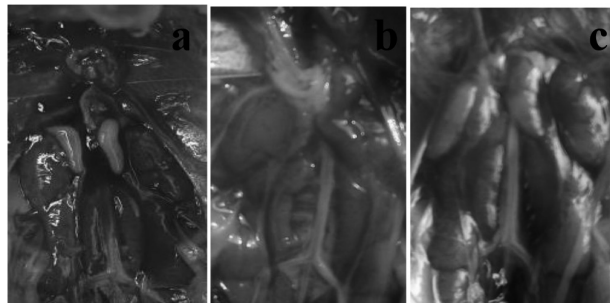


Fig. 2: Gross morphology of the gonads of male chicks at week

1. Control males showed two testes with prominent whitish colour and hard texture when touched and both testes were similar in size when appeared (a). T1 males showed a very fragile and barely developed right gonad while left gonad was well developed. However, the texture and the colour of the left gonad were pinkish and lobulated similar to female left ovary (b). T2 males showed right gonads which were less developed than control males and more developed than T1, but were very fragile. Left gonad was well developed but showed female like morphology (c).

Week 01;

Week 04;

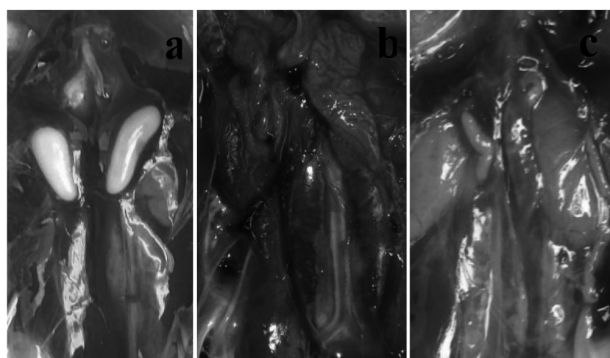


Fig. 3: Gross morphology of the gonads at week

4. Control males showed two testes with prominent whitish colour and hard texture when touched. Both testes were similar in size when appeared (a). T1 males showed a very fragile and barely developed right gonad while left gonad was well developed. The texture and morphology of left gonad were similar to female gonads (b). Right gonad was developed than T1 but not up to control. The left gonad showed the morphological similarity to female ovary (colour and form) (c).

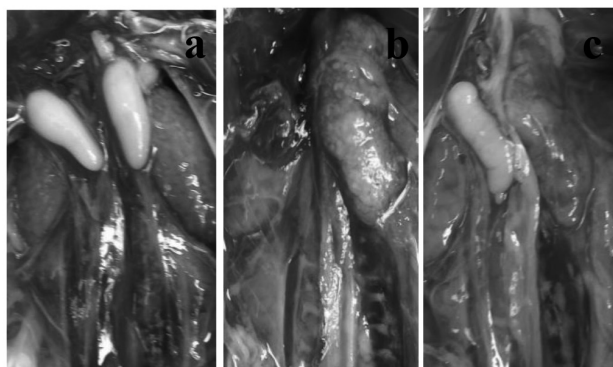


Fig. 4: Gross morphology of the gonads at week

8. Both gonads were similar in size when viewed with the naked eye. Creamy colour and bean shaped (a). Still the right gonad looked like a fragile little piece of tissue and not well developed. The left gonad was much lobulated and well grown with a pinkish colour and elastic nature (b). The left gonad was similar to female morphology while right gonad showed male morphology. Left one showed the typical lobulated nature as ovaries and was well

Morphometry of gonads:

- **Weight of gonads;**

Table 02: Statistical analysis of gonadal weight

Week	Gonad	p Value	Significance	Mean comparison
1	Left	0.2195	Not significant	
4	Left	0.4912	Not significant	
4	Right	0.6774	Not significant	
8	Left	0.0199	Significant	T1 > T2 = C
8	Right	0.0257	Significant	C > T2 = T1

- **Length of gonads;**

Table 03: Statistical Analysis of gonadal length

Week	Gonad	p Value	Significance	Mean comparison
1	Left	0.1067	Not significant	
4	Left	0.3191	Not significant	
4	Right	0.1421	Not significant	
8	Left	0.3202	Not Significant	
8	Right	0.1396	Not Significant	

- **Width of the gonads;**

Table 04: Statistical Analysis of gonadal width

Week	Gonad	p Value	Significance	Mean comparison
1	Left	0.0318	Not significant	
4	Left	0.9050	Not significant	
4	Right	0.6744	Not significant	
8	Left	0.049	Significant	T1 > T2 = C
8	Right	0.2450	Not Significant	

When the above dimensions of left gonads were compared relative to right gonad (left/right) the treatment showed no significant effect on the relative weight, length or width of the gonads.

DISCUSSION

When physical observation is considered, the gross morphology of the left gonads of treated chicks was deviated from the controls towards the female morphology with the colour and lobulated nature. This was observed in all the 3 age intervals analyzed. This same result could be observed in the previous studies by over-expressing the aromatase gene in male chickens having enlarged left gonad with similar histology to females [2],[6]. These feminized left ovaries were known as ovo-testes and were transient. This was also reported previously in the ZZW triploid chickens studies. They also had these left ovo-testes and showed inter sex features [4]. However, according to Tienhoven these left gonadal feminization was reverted back within 7 weeks of age [1]. Since we could observe the feminized left gonads even at 8th week it is important to study further about this up to sexual maturity.

When the right gonads of the treated chickens were considered it showed a significant difference among T1 and T2 where T2 which was given with the continuous estrogen treatment showed a developed right gonad than the T1 to which only in-ovo treatment was given. It has found that estrogen is important in male sexual development as well in many animal models not only in the functional aspects but also in the differentiated epithelial morphology [3]. Accordingly, we could assume that the continuous higher estrogen levels caused the development of right gonad along with the left ovo-testes. The poorly developed right gonads in T1 may indicate the inadequate estrogen to develop right gonad since the left one was well developed.

However, under the gonadal morphometry, there was no statistically significance differences reported among the treated the groups. However, there were few changes with the left gonad indicating the weight and the width of the treatment groups were significantly higher than control group. This also provides the development of left gonad with the estradiol treatment. But when the left gonadal parameters were compared relative to the right gonadal parameters, it did not show a significant treatment effect between both T2 and C groups. This shows that the treatment has no significant effect on increase of left gonad relative to right gonad and the both gonads has developed simultaneously in similar proportion to the control males although the morphology of left gonad has been affected by the estradiol treatment.

CONCLUSION

Therefore in conclusion, with the results obtained from this study, it can be suggested that, exogenous Estradiol treatment caused morphological and morphometric changes in the male gonads towards the feminization and it is persistent until the 8th week of age.

References

1. Tienhoven, A.V. "A Method of Controlling Sex by Dipping of Eggs in Hormone Solutions", *Poultry Science*, Vol.36, No. 3, pp. 628–632, 1957.
2. Vaillant, S., Dorizzi, M., Pieau, C. and Mercier N.C. "Sex Reversal and Aromatase in Chicken", *Journal of Experimental Zoology*, 290, pp. 727–740, 2001.
3. Hess, R.A. and Carnes, K. "The role of estrogen in testis and the male reproductive tract: a review and species comparison", *Animal Reproduction*, Vol.1, No.1, pp. 5-30, 2004.
4. Smith, C.A. and Sinclair, A.H. "Sex determination: insights from the chicken", *Bioessays*, 26, pp. 120-132, 2004.
5. Chue, J. and Smith, C.A. "Sex determination and sexual differentiation in the avian model", *The FEBS Journal*, 278, pp. 1027–1034, 2011.
6. Lambeth, L.S., Cummins, D.M., Doran, T.J., Sinclair, A.H. and Smith, C.A. "Overexpression of Aromatase Alone is Sufficient for Ovarian Development in Genetically Male Chicken Embryos", *Plos One*, Vol.8, No.6, pp. 68362, 2013.
7. Nirmali, W.K.R., Warnakula, L., Cooray, R., Hapuarachchi, N.S. and Magamage, M. "Comparison of DNA isolation and Dominant and Co-dominant molecular markers to reveal the genetic sex of *Gallus domesticus* (Domestic chickens)", In *Proceedings of the 2nd International Research Symposium*, Uwa Wellassa University, pp. 13, 2018.