


Case Report

An unusually late presentation of sporadic coloboma of the optic disc

Rasaiah Manmathan¹, Thirunavukarasu Kumanan², Muthusamy Malaravan¹, Vathulan Sujanitha¹

¹Teaching Hospital, Jaffna, Sri Lanka, ²Faculty of Medicine, University of Jaffna, Sri Lanka,

Key words: Optic disc coloboma, congenital anomaly of the eye, sporadic

Corresponding Author: Rasaiah Manmathan, E-mail: < rmanmathan5@gmail.com>  <https://orcid.org/0000-0001-9602-2738>

Received: May 2018, Accepted: June 2018, Published: June 2018

Competing Interests: Authors have declared that no competing interests exist

© *Authors*. This is an open-access article distributed under a Creative Commons Attribution-Share Alike 4.0 International License (CC BY-SA 4.0), which permits unrestricted use, distribution, and reproduction in any medium, provided the original author and source are attributed and materials are shared under the same license.



Introduction

Isolated bilateral sporadic optic disc coloboma is an extremely rare congenital anomaly of the eye. Optic disc coloboma is usually associated with congenital abnormalities. These may be systemic, such as congenital heart disease, renal hypoplasia, choanal atresia, growth retardation, microcephaly, short stature or malformed ears, or localized, such as microphthalmia or microcornea.

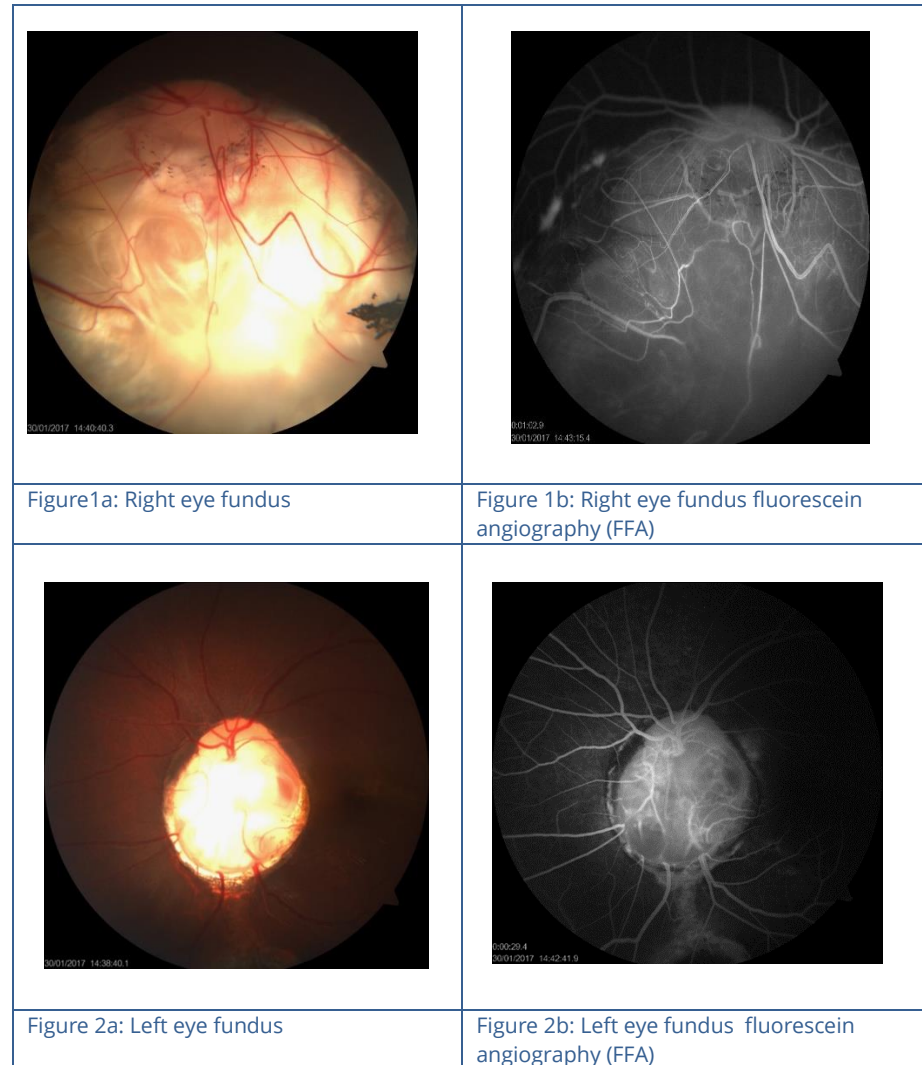
The frequencies of unilateral and bilateral optic disc coloboma are the same [1]. The lower part of the optic nerve head is occupied by the coloboma. The neuro-retinal rim is usually identifiable superiorly but absent inferiorly. Microphthalmia may also be evident in cases where the adjacent inferior retina and choroid are deficient [2].

Visual acuity is decreased to varying degrees in patients with coloboma. The only feature that relates to visual outcome is the degree of foveal involvement by the coloboma as shown by careful analysis of the photographic appearances of colobomata involving the optic nerve [3]. The visual outcome is not related to the size of the coloboma, the colour of the optic nerve or the presence of subfoveal pigment change. Significant anisometropia and refractive error are common in optic disc coloboma [3]. Neural rim decrease and progressive optic nerve cupping have been documented in a patient with bilateral autosomal dominant optic nerve colobomas with no evidence of raised intraocular pressure and, remarkably, no progressive visual field loss [4]. Histologically circumferential intrascleral smooth muscle has been observed [5] and may account for the rare observation of spontaneous contractility of the optic disc coloboma [6].

Here we present a case of isolated bilateral optic disc coloboma without systemic involvement in a young patient with chronic headache.

Case presentation

A 19-year-old boy presented to the ophthalmology outpatient department of Teaching Hospital, Jaffna with a history of chronic episodic headache for 3 years. Examination of the eye revealed a best corrected vision in the right eye of 6/60 and in the left eye of 6/9. The intraocular pressure (IOP) of the right eye was 9mmHg and of the left eye was 12mmHg. Anterior segment was normal and posterior segment showed optic disc coloboma. (Figures 1a, 1b, 2a, 2b). Contrast enhanced computerized tomography (CECT) of the brain, orbit and anterior visual pathway were performed.



The patient was referred to a general medical unit for systemic evaluation and management of headache. Detailed clinical examination was performed to rule out any congenital anomalies. Ultra sound scan of the abdomen, pelvis and neck was performed to rule out any hidden congenital structural defect. Basic renal and liver function tests and hormonal assays including TSH and cortisol were within normal limits. The patient did not have any significant past medical history or family history.

Discussion

The principal congenital abnormalities of the optic disc that can significantly impair visual function are excavation of the optic disc and optic nerve hypoplasia. Optic disc coloboma, morning glory syndrome and peripapillary staphyloma are very good examples of excavated optic disc abnormalities. These conditions can affect either one or both eyes and can impair the visual function to a varying degree.

It is very important that children with poor vision due to any of the above conditions are managed by treating refractive errors, providing occlusion therapy in selected cases, and optimizing the conditions at school or home in an attempt to ensure that visual impairment does not affect development or education.

Here we report a boy who presented with chronic headache in his late teens and was found to have an optic coloboma. There were no congenital anomalies detected in our patient after an extensive laboratory and imaging workup. Microphthalmia or microcornea were not evident. Parents and siblings were screened for optic disc coloboma and were found to be negative. Ultrasonography of abdomen showed normal sized kidneys without any altered architecture which reasonably rules out a PAX2 mutation. Further studies excluded dysgenesis of the internal carotid artery or transphenoidalencephalocele with hypopituitarism. The optic disc coloboma was not associated with a cyst arising from the optic nerve sheath or retina. A diagnosis of isolated sporadic bilateral optic disc coloboma was made.

There is no specific treatment required in these patients. Low vision aids may be helpful in certain patients. Optimal refractive correction would be indicated in children if they present early.

Conclusion

Isolated sporadic bilateral coloboma was an incidental finding in our patient who came with chronic headache. Congenital anomalies were reasonably ruled out by examination and imaging studies.

Declarations

Consent for Publication

Informed written consent for the publication of clinical details and images was obtained from the patient and his father.

Acknowledgements

We acknowledge and thank the patient who agreed for the publication of his case.

References

1. Pollock S. The morning glory disc anomaly: contractile movement, classification, and embryogenesis. *Documenta ophthalmologica*. 1987 Apr 1;65(4):439-60. <https://doi.org/10.1007/BF00143047> PMID:3319466
2. Brodsky MC. Congenital anomalies of the optic disc. In Walsh & Hoyt's *Clinical Neuro-ophthalmology* 2005 (pp. 151-196). Lippincott Williams & Wilkins, Philadelphia.
3. Olsen TW, Summers CG, Knobloch WH. Predicting visual acuity in children with colobomas involving the optic nerve. *Journal of pediatric ophthalmology and strabismus*. 1996 Jan 1;33(1):47-51. PMID:8965225
4. Moore M, Salles D, Jampol LM. Progressive optic nerve cupping and neural rim decrease in a patient with bilateral autosomal dominant optic nerve colobomas. *American journal of ophthalmology*. 2000 Apr 1;129(4):517-20. [https://doi.org/10.1016/S0002-9394\(99\)00463-8](https://doi.org/10.1016/S0002-9394(99)00463-8)
5. Font RL, Zimmerman LE. Intrasccleral smooth muscle in coloboma of the optic disk: Electron microscopic verification. *American journal of ophthalmology*. 1971 Aug 1;72(2):452-7. [https://doi.org/10.1016/0002-9394\(71\)91318-3](https://doi.org/10.1016/0002-9394(71)91318-3)
6. Foster JA, Lam S. Contractile optic disc coloboma. *Archives of ophthalmology*. 1991 Apr 1;109(4):472-3 <https://doi.org/10.1001/archopht.1991.01080040040016>