

Isolated Spinal Langerhans Cell Histiocytosis is a Close Mimic of Pott's Disease in the Tropics

Solangaarachchige Anushika Luckmy*¹, Thirunavukarasu Kumanan², Navaneethakrishnan Suganthan³, Selvaratnam Gowry⁴, Sheyamalan Pathmini⁵, Niluka Ranathunga⁶

¹Registrar in General Medicine, Teaching hospital Kandy, Sri Lanka

²Consultant Physician and senior lecturer, Department of Medicine, Faculty of Medicine, University of Jaffna, Sri Lanka

³Consultant Physician and senior lecturer, Department of Medicine, Faculty of Medicine, University of Jaffna, Sri Lanka

⁴Consultant Chest Physician and senior lecturer, Department of Medicine, Faculty of Medicine, University of Jaffna, Sri Lanka

⁵Consultant Radiologist, Department of Radiology, Teaching hospital, Jaffna, Sri Lanka

⁶Consultant Histopathologist, Department of Histopathology, Teaching hospital, Jaffna, Sri Lanka

Case Report

*Corresponding author

Solangaarachchige
Anushika Luckmy

Article History

Received: 15.04.2018

Accepted: 24.04.2018

Published: 30.04.2018

DOI:

10.21276/sjpm.2018.3.4.5



Abstract: Spinal tuberculosis (pott's disease) is a common manifestation of extrapulmonary tuberculosis. Spinal langerhans cell histiocytosis is also a granulomatous condition which can resemble pott's disease in many aspects. In the tropics where pott's disease is common, diagnosis of spinal langerhans cell histiocytosis may be masked. We describe a case of recurrent langerhans cell histiocytosis with a long lag period whereas the first presentation was compatible with spinal langerhans cell histiocytosis on retrospective analysis. This case highlights the importance of high index suspicion of langerhans cell histiocytosis in the tropical medicine.

Keywords: langerhans cell histiocytosis, mimicker, pott's disease, tropical countries, vertebra plana.

INTRODUCTION

Langerhans cell histiocytosis (LCH) is a unique systemic disorder. At present LCH is no longer rare according to the current medical literature. LCH is said to occur due to an abnormal proliferation of histiocytes called as langerhans' cells [1]. As it is multisystemic, LCH can be present with an array of clinical manifestations. It is extremely important to promptly diagnose the condition and institute early treatment to prevent disease progression. This case report describes a diagnostic dilemma encountered in diagnosing spinal LCH in the tropic where tuberculosis is highly prevalent.

CASE REPORT

A nine year old previously healthy boy presented following a sudden fall on the ground due to weakness of lower limbs in the background history of progressive weakness of lower limbs for two weeks duration. He had no back pain, urinary or faecal incontinence. He had no fever or constitutional symptoms. His symptoms were associated with numbness of lower body. He did not complain of any history of cough, night sweats or haemoptysis. He did not have personal or contact history of tuberculosis. There was no significant family history of similar neurological disorders. He denied major injuries or falls in the past.

On examination, he was conscious with 15/15 of Glasgow coma scale and well looking. He was afebrile. His haemodynamic parameters were stable. BCG scar was noted on the left deltoid area. There were

symmetrically hypotonic lower limbs with the muscle power of grade II, hyporeflexia and sensory level at T5 level for all modalities including pain, touch and vibration sensation. His upper limbs were neurologically normal with absent cerebellar signs. He had an upper thoracic deformity and an expanding bony lump in the upper trunk at the back. Anal sphincter tone was normal. No detectable urinary dribbling on observation.

Basic laboratory investigation revealed WBC 5800/mm³, neutrophils 77%, lymphocytes 20%, Haemoglobin 12.2 g/dl, platelets 224000/mm³. ESR was 50mm/first hour and CRP 12. His presentation was compatible with acute onset paraplegia associated with the compression of spinal cord at the level of T4. Magnetic resonance imaging of spine showed a solitary vertebral collapse at T4 level and a paravertebral mass at the same level. Histology from CT guided biopsy of

paravertebral mass revealed a malignant round cell tumour with ganglion cells. Polymerase chain reaction for tuberculosis bacillus from paravertebral mass was negative. According to the clinical findings patient was treated as Pott's disease with antituberculous therapy for a year. He made a complete recovery from his neurological symptoms. Thereafter he was clinically asymptomatic for 10 years.

He represented with a localized headache involving right sided occipital region for duration of one month at the age of 19 years. He had no similar problems in the past and had no trauma or surgery to head and neck. He had no fever, vomiting, visual disturbances or any other neurological symptoms. He

did not report any episodes of loss of consciousness or seizures or any constitutional symptoms. On examination he had a mild tenderness over right occipital region and rest of the clinical examination was unremarkable including fundoscopy. A laboratory work up including blood counts, inflammatory markers, renal and liver profile were normal. Contrast enhanced computer tomography of head revealed a single lytic lesion in the right occipital bone and there were no other lytic areas elsewhere in the skull. Brain imaging was within normal limits.

A probable diagnosis of LCH was considered and a skull bone biopsy concluded the histological diagnosis of langerhans cell histiocytosis.

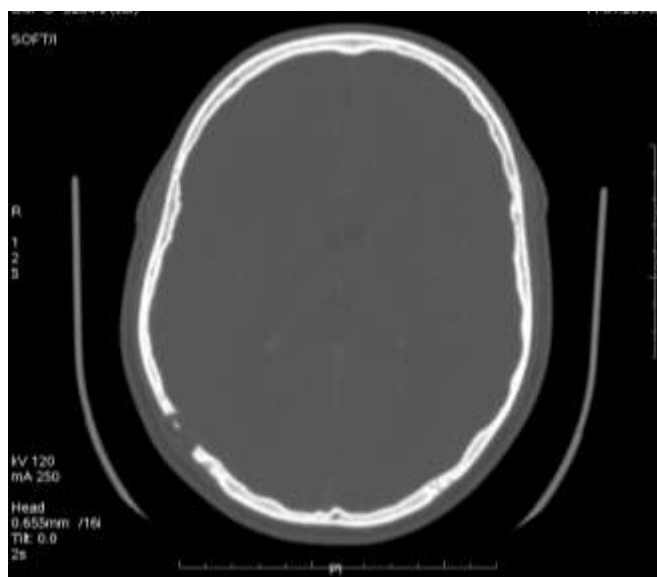


Fig-1: Computer tomography scan of head shows a full thickness single lytic lesion in the right occipital bone.

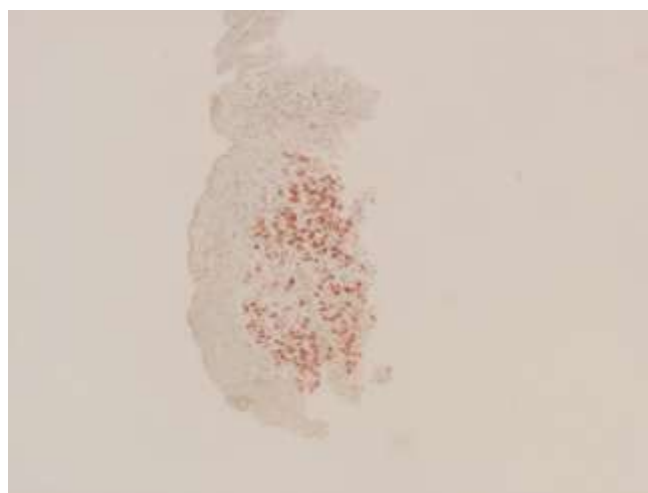


Fig-2: Immunohistochemical staining of skull bone lytic lesion with Cd 1a shows scattered and clusters of Cd 1a positive cells within the inflammatory tissue fragments. Cd 1a is the characteristic marker for langerhan cell histiocytosis

Systemic involvement of langerhans cell histiocytosis was excluded. CECT scan showed a vertebral plana of T4 vertebral body with kyphus deformity with mild spinal canal narrowing. Patient was referred to oncology and given local radiotherapy.

DISCUSSION

LCH is a great mimicker of spinal tuberculosis (TB). Since spinal TB is highly prevalent in tropical countries like Sri Lanka, hence it possess a great challenge to the treating clinician in differentiating both LCH and spinal TB as they share similar clinical manifestations. As confirmatory diagnosis of LCH is a challenging task in this part of the world, it is apparently under diagnosed and undertreated.

Here we describe the overlapping symptoms and distinguishable features of spinal TB and LCH. Pott's disease is a common form of extrapulmonary tuberculosis prevalent in tropical countries. Pott's disease occurs typically in lower thoracic and upper lumbar vertebrae region mainly at the thoraco-lumbar junction. Skull is the most frequently involved bony structure in LCH followed by vertebrae including upper thoracic (T2-T5), cervical, lumbar in order. The Symptomatology is almost similar to both conditions, comprising of back pain or neck pain, reduced spinal movements, neurological deficits and deformities. Spinal cord and root compression is a devastating consequence of both spinal LCH and potts' disease [2]. LCH is a disease of children and adolescents. We encounter pott's disease in all age groups but common in young adults. Radiological findings of LCH and pott's disease are completely different but in real practice these may resemble each other. Intervertebral joint space is lost in pott's disease and multiple vertebrae are affected with destructed anterior aspects of vertebral bodies. Well preserved disc space, vertebra plana, solitary vertebral collapse are characteristic for LCH. Vertebra plana is also can be a feature of pott's disease. Both LCH spine and pott's disease in histopathology reveal granuloma with histiocytes. Spinal TB would show caseating granulomas rich in lymphocytes. LCH characterized by large round like noncaseating granulomas rich in eosinophils [3]. Although there is a definitive criteria to diagnose LCH of spine, it is a clinico-radio-pathological diagnosis. Our patient improved after a course of oral corticosteroids, which was given with antituberculoid therapy in the initial period. The diagnosis was misinterpreted as spinal TB due to the similarity of clinical features in particular absence of extra spinal involvement. There were lack of confirmatory diagnostic tests in this part of the world almost a decade ago. The diagnosis was further supported by a prompt response to steroids along with antituberculoid therapy. Response to steroids is well-known and infact complete resolution of LCH has occurred according to the literature. Unifocal spinal LCH has a good prognosis. There are few reported cases with spontaneous resolution of LCH [4].

CONCLUSION

LCH spine closely resembles pott's disease in many ways. LCH spine can be easily mistaken as pott's disease. It should be highly taken in to consideration by clinicians especially where there TB is prevalent. We emphasize that clinicians in tropics need greater awareness of LCH spine and LCH has to be considered in the list of differential diagnosis, when approaching a case with possible spinal TB.

Consent for publication

Written informed consent was obtained from the patient for publication of case report and images.

Competing interests

All authors declared that they have no competing interests.

Acknowledgements

We acknowledge the medical teams who had treated the patient during the first presentation.

REFERENCES

1. Sadashiva, N., Rajalakshmi, P., Mahadevan, A., Vazhayil, V., Rao, K. N., & Somanna, S. (2016). Surgical treatment of Langerhans cell histiocytosis of cervical spine: case report and review of literature. *Child's Nervous System*, 32(6), 1149-1152.
2. Bertram, C., Madert, J., & Eggers, C. (2002). Eosinophilic granuloma of the cervical spine. *Spine*, 27(13), 1408-1413.
3. Malpas, J. S. (1998). Langerhans cell histiocytosis in adults. *Hematology/Oncology Clinics*, 12(2), 259-268.
4. Rajendram, R., Rose, G. E., Luthert, P. J., Plowman, P. N., & Pearson, A. R. (2005). Biopsy-confirmed spontaneous resolution of orbital langerhans cell histiocytosis. *Orbit*, 24(1), 39-41.