



Case Report

Scimitar syndrome: A rare cause of right sided palpitations in an adult

Perera, I.A.¹, Kumanan, T.¹, Guruparan, M.², Rangunathan, I.R.²

¹ University medical unit, Teaching Hospital Jaffna, Sri Lanka.

² Cardiology Unit, Teaching Hospital Jaffna, Sri Lanka.

Corresponding author Perera, I.A Email: irushna_p@yahoo.co.in

Abstract

Scimitar syndrome is a constellation of rare, congenital, cardiopulmonary anomalies, comprising of partial anomalous pulmonary venous connection of the right lung to the inferior vena cava(IVC), hypoplasia of the right lung, dextroposition of the cardia and an anomalous systemic arterial supply to the right lung, the salient defect being the anomalous right pulmonary vein which drains part or all of the right lung into the IVC. The presentation may be in infancy or in adulthood. Infants may present with respiratory distress, heart failure or with severe pulmonary hypertension, and in some asymptomatic infants it may even be an incidental diagnosis. The adult form typically presents with minimal symptoms and carries a benign prognosis, especially in the absence of pulmonary hypertension. Here we report a case of Scimitar syndrome, in an otherwise healthy young woman, who presented with an unusual symptom of palpitations over the right side of the chest. The adult form of this syndrome has never been reported from Sri Lanka before.

Introduction

Scimitar syndrome is a rare, congenital, cardiopulmonary defect presenting as an anomalous right pulmonary vein draining directly into the IVC, in association with a hypoplastic right lung, a hypoplastic right pulmonary artery, with a resultant shift of the mediastinum into the right hemi thorax, with or without an anomalous systemic arterial supply to the right lung. The symptomatology may vary, depending on the age at presentation and the prognosis will depend on the presence or absence of pulmonary hypertension or its severity on diagnosis.

Case presentation

A 26-year-old apparently healthy female was seen at the out-patient medical clinic, referred by a general practitioner for further evaluation of an unusual symptom of intermittent palpitations over the right side of the chest of 4 months duration. She was otherwise in good health and had no other symptoms of concern.

The palpitations were noticed to occur usually after exertion or during a stressful situation and used to subside spontaneously within a few minutes. She did not complain of chest pain or feeling light headed during these episodes. She had a good exercise tolerance and denied recent weight loss, loose stools or excessive sweating suggestive of hyperthyroidism.

Inquiry into her past medical history did not reveal any recurrent chest infections or cardiac diseases in her childhood. She was a nonsmoker and did not consume alcohol.

On examination, she was comfortable and did not appear to be pale or cyanosed and had no goitre, clubbing, peripheral cyanosis or lymphadenopathy. She had a pulse rate of 88 beats/minute, which was regular, a blood pressure of 110/76mmHg and a respiratory rate of 16 cycles/min. There were no obvious chest wall deformities. The percussion note was normal over the chest and the auscultation of the chest revealed mild reduction in breath sounds over the right base, however no added sounds were heard. The O₂ saturation on ambient air was 97%. The apex beat was difficult to localize and the heart sounds were soft. There were no appreciable murmurs or palpable thrills. Abdomen examination was clinically unremarkable.

An electrocardiogram which was done on presentation was normal apart from a dominant 'R' wave in V1. Basic blood investigations including a full blood count, inflammatory markers, renal and liver profile were normal. A chest radiograph revealed a shift of the mediastinum towards the right hemithorax, reduced volume of the right hemithorax and 2 linear opacities spanning across the right lung (Fig 1).

Expert opinion was taken from the consultant radiologist and a possibility of Scimitar syndrome was suggested with evidence of a hypoplastic right lung with an anomalous pulmonary venous drainage.

A contrast enhanced computerized tomography of the thorax and upper abdomen, confirmed the diagnosis of Scimitar syndrome, as evidenced by a hypoplastic right lung with a small pulmonary artery and 2 anomalous pulmonary veins being fused and forming a single anomalous vein



Case Report

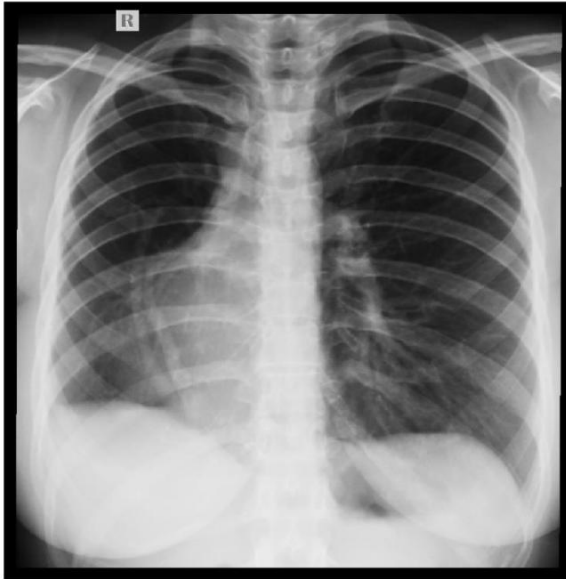


Figure 1- The chest radiograph revealing the Scimitar vein, a shift of the mediastinum towards the right hemithorax and a reduced volume of the right hemithorax.

before draining into IVC at the junction of the right atrium and the IVC. Mediastinum was shifted to the right and there were no obvious systemic vessels arising from the descending aorta.

A 2D Echocardiogram was performed to look for evidence of pulmonary hypertension, which revealed dextroposition of the heart, normal systemic venous drainage and the right middle and lower pulmonary veins draining into the IVC, dilated right atrium and ventricle, with an intact inter atrial septum, mild tricuspid regurgitation and mild pulmonary hypertension with a pressure gradient of 27mmHg.

Cardiac catheterization confirmed the echocardiographic findings and also confirmed the presence of mild pulmonary hypertension. (Fig 2) The nature of her condition was explained to the patient and due to the presence of a dilated right atrium and right ventricle and the risk of progressive pulmonary hypertension, she was recommended for surgical redirection of the right sided pulmonary veins to the left atrium.

She was referred to a specialized center for cardiothoracic surgery, underwent successful surgical correction and had an uneventful recovery.

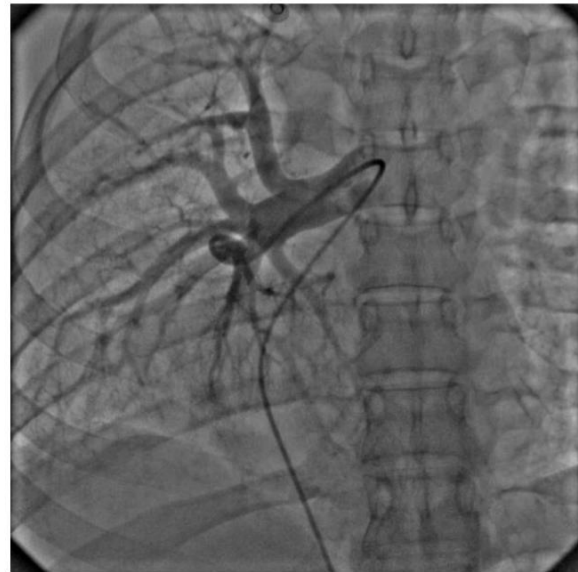

Figure 2a- RPA angiogram showing hypoplastic branch pulmonary arteries

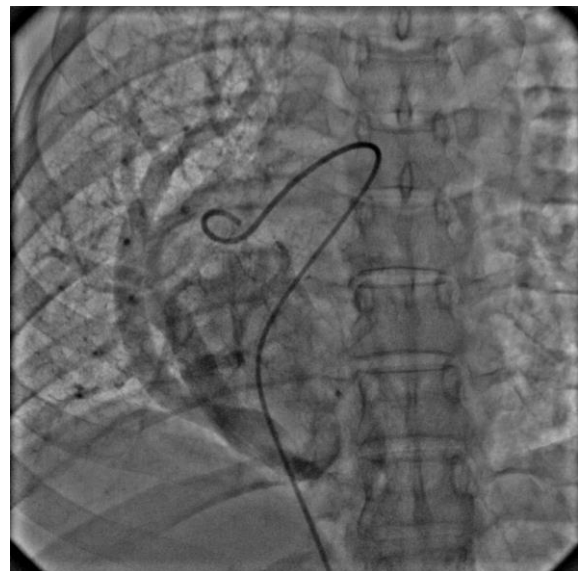


Figure 2b- Levophase of RPA angiogram showing the scimitar vein draining into IVC

Discussion

Scimitar syndrome, also known as “Pulmonary venolobar syndrome”, comprises of an anomalous right pulmonary venous drainage to the IVC, which may be partial or complete. The additional anomalies which may occur in association are, hypoplasia and abnormal vascular supply to the right lung, dextroposition of the cardia, and abnormalities of bronchial segmentation. Bronchiectasis is usually rare [1]. The term dextroposition is preferred over dextrocardia, as the heart, even though shifted to the right hemithorax, maintains a normal orientation of its chambers, and the apex remains directed towards the left [2].



Right sided palpitation is an unusual presentation of this condition. The anomalous pulmonary vein, on the chest radiograph, usually appears as a radio-opaque, curvilinear shadow, extending downwards from the upper zone of the right lung, towards the right heart border, with an increase in its caliber on reaching the right cardio-phrenic angle (In our case, 2 curvilinear shadows, joining towards the lung base to form a single vein before draining into the IVC). This appearance has been likened to a curved Turkish sword or “Scimitar”, from which the name has been coined by Naill in 1960[3].

The condition is rare with an incidence of approximately 1 to 3 in 100,000 live births [1].

Due to the anomalous pulmonary venous drainage, a left to right shunt is established, with blood from the right lung draining directly into the IVC, which may lead to volume overload of the right atrium and the right ventricle with risk of developing right ventricular failure [4]. The condition may become apparent in infancy presenting as tachypnea, cyanosis, failure to thrive, pulmonary hypertension and is known to be associated with cardiac defects, commonly atrial septal defect, many of which require surgical correction

Pulmonary hypertension is often the cause of severe symptoms and poor prognosis. In older children and adults, the disease commonly presents with recurrent chest infections or exertional dyspnea, but usually runs a benign course [5].

Rare presentations among adults, such as hemoptysis, pulmonary hypertension have been mentioned in the literature but a presentation with palpitations alone, revealing a diagnosis of isolated Scimitar syndrome without other congenital defects, has not been reported in the literature from this part of the world [5].

A diagnosis can easily be made by a chest radiograph and a transthoracic or transoesophageal echocardiogram and can be confirmed by CT angiogram, Magnetic Resonance Angiogram (MRA) or by cardiac catheterization. Prenatal diagnosis is also possible by fetal echocardiography[6].

The management of the condition depends on the hemodynamic parameters of the patient, along with the presence or absence of pulmonary hypertension. If the volume of blood reaching the IVC via the anomalous vein is small, intervention may not be required. In the presence of a significant shunt from left to right along with pulmonary hypertension, surgical repositioning is advised. Intra cardiac repair of Scimitar syndrome, in patients without pulmonary hypertension is known to carry an excellent prognosis [3].

Surgical correction was carried out in our patient, who was found to have a dilated right atrium and right ventricle with mild pulmonary hypertension (27mmHg) and went on to make an uneventful recovery.

Conclusion

The unusual presentation of this patient as intermittent palpitations over the right side of the chest, following a few basic investigations, led to a diagnosis of a rare congenital cardiac anomaly. The timely diagnosis and early surgery, prior to her developing any complications, will give her a near normal life. We wish to highlight the importance of not ignoring minor and unusual complaints and detecting subtle but significant changes in freely available investigations such as electrocardiogram and chest radiograph and how this improved vigilance will improve the standard of patient care.

Acknowledgements

We wish to thank Dr. K. Sivasethambaram, Consultant Radiologist and all the members of hospital staff who helped us in management of this patient, and in carrying out the diagnostic procedures and all those who helped us to publish the case report.

Conflicts of interest

The authors declare that they have no conflict of interests.



Consent for publication

Written informed consent was obtained from the patient for publication of this case report

References

1. Dupuis, C., et al., *The "adult" form of the scimitar syndrome*. Am J Cardiol, 1992. **70**(4): p. 502-7.
2. Azhari, N., F. Al-Fadley, and Z.R. Bulbul, *Tetralogy of Fallot associated with scimitar syndrome*. Cardiol Young, 2000. **10**(1): p. 70-2.
3. Kahrom, M. and H. Kahrom, *Scimitar syndrome and evolution of managements*. Pan Afr Med J, 2009. **3**: p. 20.
4. Kamler, M., et al., *Scimitar syndrome in an adult: diagnosis and surgical treatment*. Interact Cardiovasc Thorac Surg, 2003. **2**(3): p. 350-1.
5. Gupta, M.L., R. Bagarhatta, and J. Sinha, *Scimitar syndrome: A rare disease with unusual presentation*. Lung India, 2009. **26**(1): p. 26-9.
6. Bhide, A., et al., *Prenatal findings and differential diagnosis of scimitar syndrome and pulmonary sequestration*. Ultrasound Obstet Gynecol, 2010. **35**(4): p. 398-404.

