

A rare cause of acute abdomen: torsion of a second spleen

S Gobishangar, S Raviraj

Ceylon Medical Journal 2013; 58: 34-35

Introduction

Congenital abnormalities of the spleen are not uncommon. Commonest abnormality is the occurrence of accessory spleens (splenunculi). However the presence of a second spleen is very rare. While the size and shape of an accessory spleen can vary markedly, a second spleen is almost identical to the normal spleen morphologically. Torsion in a second spleen is a rare clinical entity and its diagnosis is very difficult. It is due to abnormal anatomical position with a long pedicle and absence or laxity of suspensory ligaments compared to the normal spleen [1].

Case report

A 12-year old previously healthy girl was admitted to the hospital with two days of upper abdominal pain. The pain was constant and moderate and was not associated with nausea or vomiting. Her bowel habits were normal prior to this illness.

On examination her temperature was 37.5°C, blood pressure was 90/60 mmHg and the pulse rate was 92/min. The abdomen was slightly distended with tenderness, rigidity and guarding. The abdominal signs were more marked in the epigastrium and left upper quadrant.

Laboratory investigations were normal except for leukocytosis. The X-ray abdomen and erect chest X-ray were normal. Abdominal ultrasound scan revealed a solid mass in the epigastric region. Liver, spleen, gall bladder and kidneys were normal.

At surgery a haemorrhagic, infarcted second spleen was located in the greater omentum, identical to the normal spleen morphologically. This second spleen was about 7.0 × 4.0 × 3.5cm with a long pedicle. The normal spleen was situated in the expected anatomical position (Figures 1 and 2). The removed second spleen showed infarcted, necrotic spleen tissues and thrombosis of the hilar vessels microscopically. Polyvalent pneumococcal vaccine was not administered postoperatively due to the presence of a normal spleen.

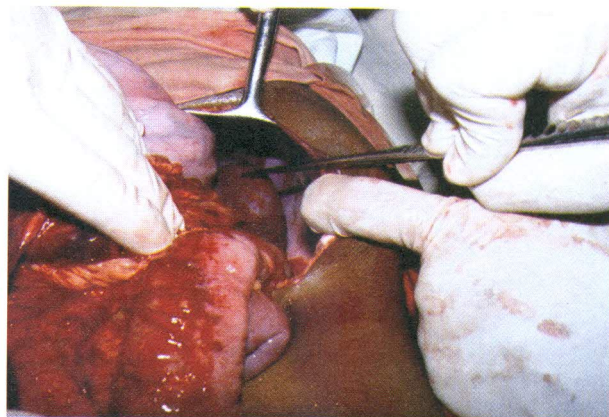


Figure 1. The normal spleen in the left hypochondrium.

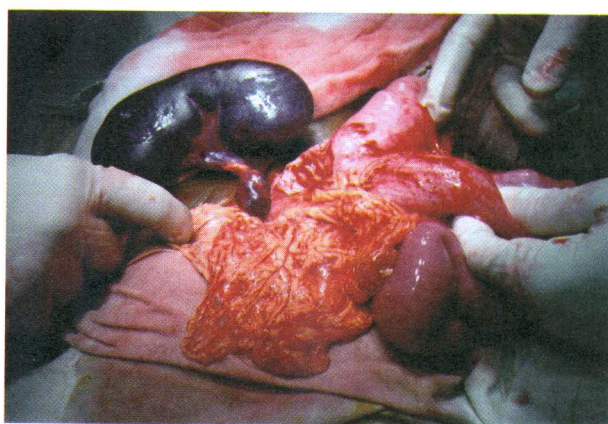


Figure 2. Accessory spleen in the greater omentum with a long twisted pedicle and with no supporting ligaments.

Discussion

The spleen develops in the left hypochondrium of the abdomen from the mesenchymal cells of dorsal mesogastrium. The gastrosplenic, splenocolic, splenophrenic and splenorenal ligaments maintain the spleen in its anatomical position. The congenital absence or laxity

Department of Surgery, Faculty of Medicine, University of Jaffna, Sri Lanka.

Correspondence: SG, e-mail: <gobishangar@gmail.com>. Received 22 May and revised version accepted 11 October 2012. Competing interests: none declared.

of these ligaments facilitate the free mobility of the spleen and allow the splenic pedicle to elongate predisposing to torsion.

Accessory spleen (supernumerary spleen, splenule or splenunculus) is usually a small nodule of splenic tissue found apart from the main body of the spleen. An accessory spleen is found in 10% of population [2]. They form either by the result of developmental anomalies or trauma [3]. But there is little information available about the second spleen. The typical size of an accessory spleen may vary from 1 to 3 cm and can take any shape [1]. This girl had a second spleen which is identical in size and morphology to the normal spleen.

Acute complete splenic torsion may present as fever, signs of peritonitis and pressure symptoms on other organs [3,4]. The consequences of splenic torsion can be dangerous. The occlusion of splenic vessels may lead to haemorrhagic infarction of the entire spleen, splenic

gangrene, perisplenic adhesions and splenic cysts or abscess [4]. Abdominal ultrasound, CT, scintigraphy and angiography have been used for the diagnosis of splenic torsion. Preoperative diagnosis is usually difficult and the diagnosis is made only at laparotomy.

References

1. Gayer G, Zissin R, Apter S, *et al.* CT findings in congenital anomalies of the spleen. *British Journal of Radiology* 2001; **74**: 767-72.
 2. Keith L Moore. Clinically oriented anatomy. 3rd edition. Baltimore: Williams & Wilkins, 1992.
 3. Michaels L. Spontaneous torsion of spleen involving tail of Pancreas. *Lancet* 1954; **267**: 23.
 4. Frederik HB, Khettry J, Filler RM. Splenic torsion and accessory spleen. *Journal of Paediatric Surgery* 1975; **10**: 913.
-